



## PATIENT PRESENTING CLINICAL SIGNS

Ruger Willow Reeter Just finished Chemo treatment for hemangiosarcoma on 2/5/26.  
Now is painful in pelvis with some edema in right hock developing today

**SPECIES** Abnormal PE/Chem/CBC/UA Results: Suspicious area seen on radiographs of pelvis on 2/11/26

Canine **COMPUTED TOMOGRAPHIC STUDY OF THE PELVIS**

Plain and post contrast studies are available for review.

**BREED** **COMPUTED TOMOGRAPHIC FINDINGS**

Boxer An aggressive primitive lytic lesion with associated amorphous periosteal new bone formation is seen in the left sciatic bone. Margins are poorly defined with long indistinct transition zones consistent with aggressive osseous disease.

**SEX**

FS Severe degenerative lumbosacral stenosis is noted with caudal lumbar and lumbosacral spondylosis deformans.

**AGE**

The left stifle presents osteoarthritic changes with a history of cruciate ligament injury and TPLO being evident. Severe atrophy of the left hind limb musculature is noted.

11yr

The right caudal thigh musculature presents an ill-defined cavitory mass measuring ~ 7 x 4 cm with irregular peripheral enhancement located just distal to the right sciatic bone.

**INTERPRETED BY**

Nele Eley (Ondreka),  
DVM Dr. med. vet.,  
DipECVDI

Right inguinal fat stranding is present.

Mild enlargement of the right medial iliac lymph node is noted.

No additional skeletal aggressive osteolytic lesions are identified.

**HOSPITAL NAME**

Green Prairie AH

**COMPUTED TOMOGRAPHIC DIAGNOSIS**

- Aggressive primitive lytic lesion of the left sciatic bone highly suspicious for osseous metastasis or less likely primary bone neoplasia.
- Cavitory soft tissue mass in the right caudal musculature, differential includes soft tissue metastasis and less likely hematoma or abscess.
- Extensive soft tissue edema and fat stranding in the right inguinal region.
- Mild right medial iliac lymphadenomegaly
- Severe left hind limb muscle atrophy, disuse or neurogenic in etiology
- Degenerative lumbosacral stenosis
- Left stifle osteoarthritis post TPLO

**REFERRING VET**

Dr Gretchen Lampe

**INVOICE**

23874

**INTERPRETATION OF FINDINGS & FURTHER RECOMMENDATIONS**

**DATE**

02/12/2026

The findings are strongly concerning for multifocal neoplastic disease compatible with metastatic spread of hemangiosarcoma given the recent history. The left sciatic bone lesion demonstrates aggressive features. The right caudal thigh cavitory mass could represent a soft tissue metastasis,



**PATIENT**

hemorrhagic mass or post-traumatic hemorrhagic collection. Abscess is considered unlikely but can never be ruled out entirely.

Ruger Willow Reeter

The right medial iliac lymphadenomegaly may represent reactive or less likely metastatic involvement.

**SPECIES**

Canine

The severe muscle atrophy of the left hind likely reflects chronic disuse secondary to sciatic involvement.

**BREED**

Boxer

Tissue sampling of the left sciatic bone lesion and/or right thigh soft tissue mass are recommended for definitive diagnosis.

**SEX**

FS

**AGE**

11yr

**INTERPRETED BY**

Nele Eley (Ondreka),  
DVM Dr. med. vet.,  
DipECVDI

**HOSPITAL NAME**

Green Prairie AH

**REFERRING VET**

Dr Gretchen Lampe

**INVOICE**

23874

**DATE**

02/12/2026



## PATIENT

Ruger Willow Reeter

## SPECIES

Canine

## BREED

Boxer

## SEX

FS

## AGE

11yr

## INTERPRETED BY

Nele Eley (Ondreka),  
DVM Dr. med. vet.,  
DipECVDI

## HOSPITAL NAME

Green Prairie AH

## REFERRING VET

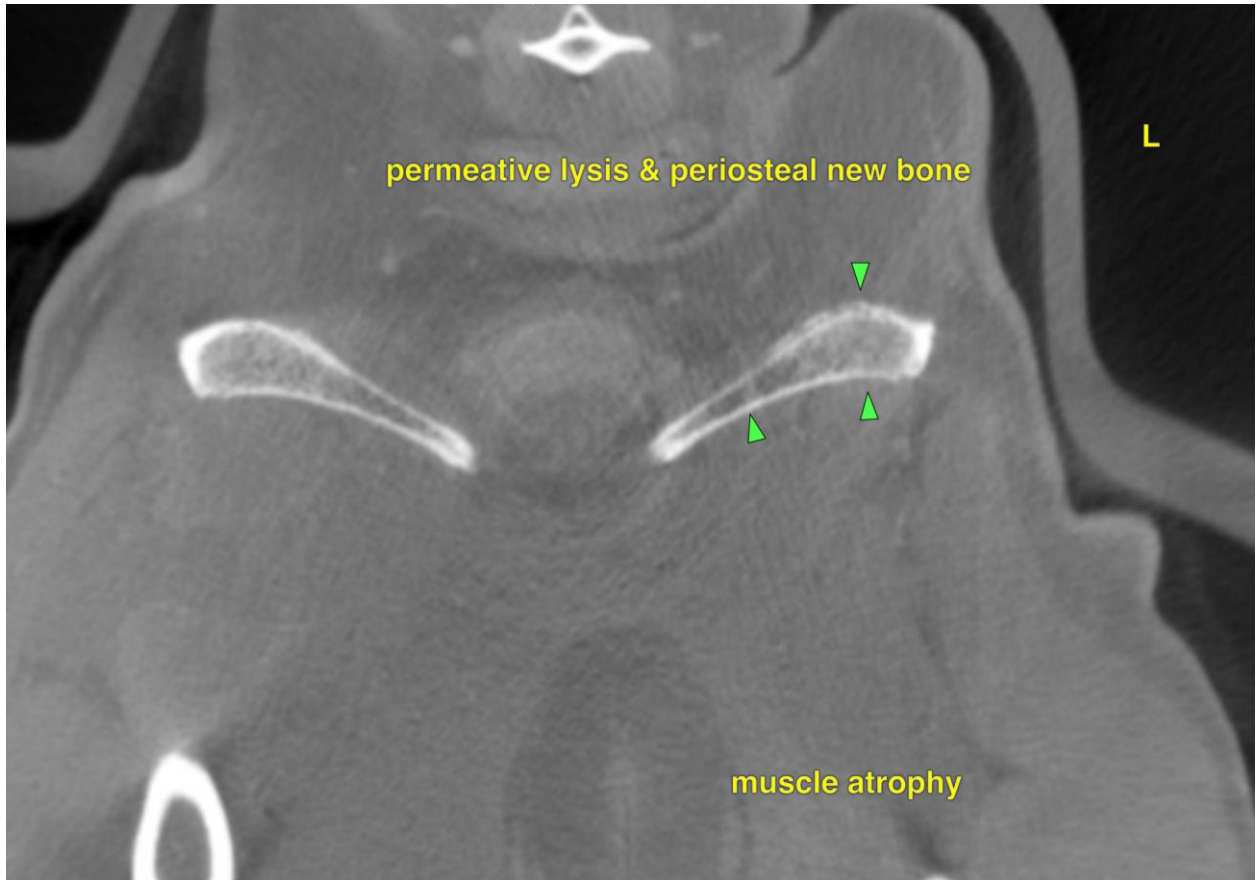
Dr Gretchen Lampe

## INVOICE

23874

## DATE

02/12/2026





### PATIENT

Ruger Willow Reeter

### SPECIES

Canine

### BREED

Boxer

### SEX

FS

### AGE

11yr

### INTERPRETED BY

Nele Eley (Ondreka),  
DVM Dr. med. vet.,  
DipECVDI

### HOSPITAL NAME

Green Prairie AH

### REFERRING VET

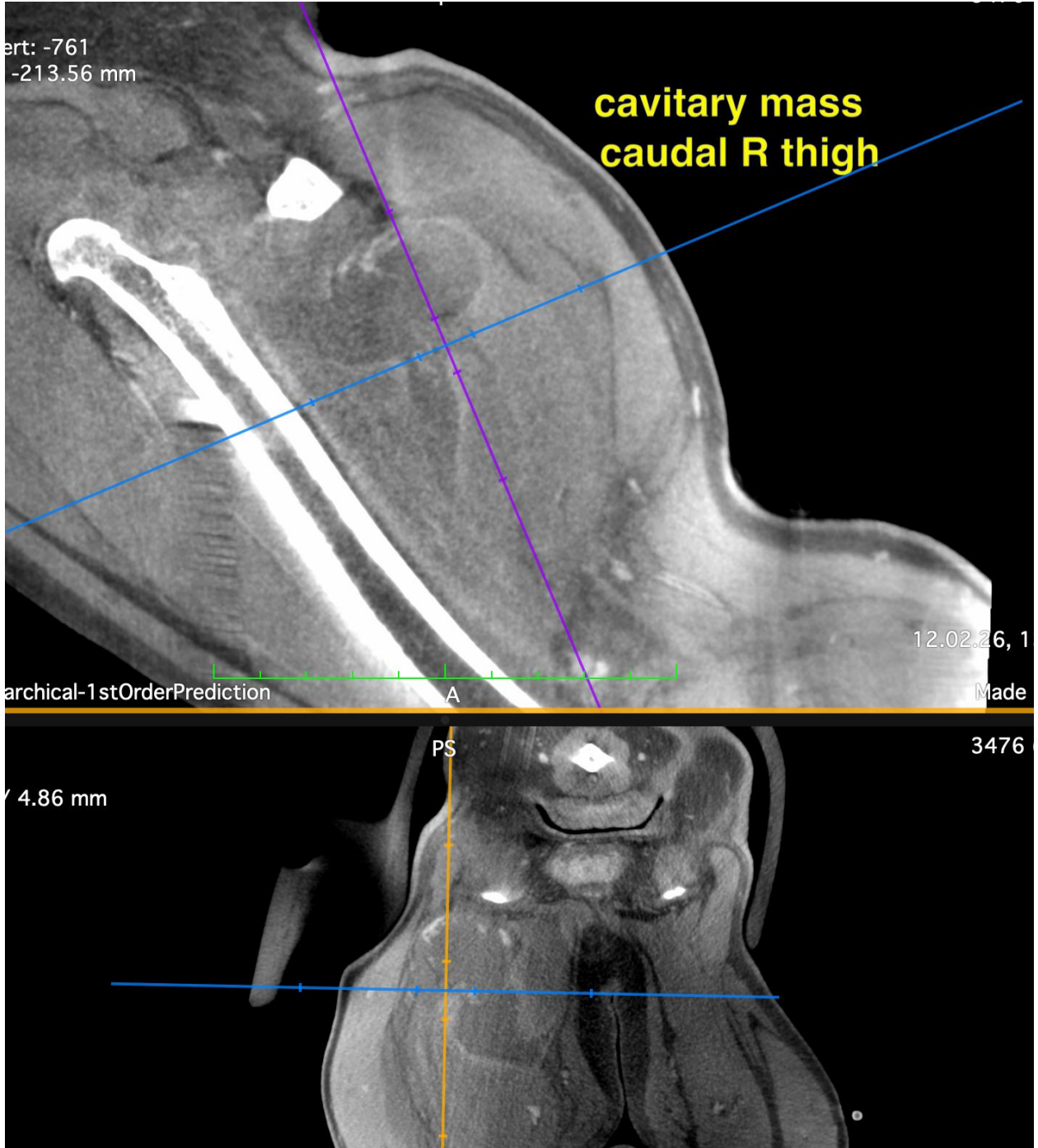
Dr Gretchen Lampe

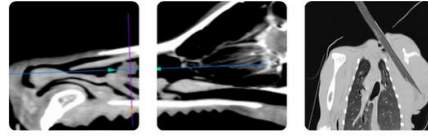
### INVOICE

23874

### DATE

02/12/2026





## PATIENT

Ruger Willow Reeter

The information and recommendations provided are based on the images presented by the referring veterinarian. No evaluation can be communicated regarding pathology that was not visible in the image/video clips provided.

## SPECIES

Canine

Thank you for this referral. If the clinical or image interpretation does not parallel your findings or if I can be of any further assistance please contact me.

## BREED

Boxer

**Nele Eley (Ondreka)**, DVM, Dr. med. vet., DipECVDI  
European Specialist in Veterinary Diagnostic Imaging, Cert. Radiology,  
Senior lecturer University of Giessen/Germany, Veterinary Faculty, Department of Radiology.  
[info@sonopath.com](mailto:info@sonopath.com)

## SEX

FS

## AGE

11yr

## INTERPRETED BY

Nele Eley (Ondreka),  
DVM Dr. med. vet.,  
DipECVDI

## HOSPITAL NAME

Green Prairie AH

## REFERRING VET

Dr Gretchen Lampe

## INVOICE

23874

## DATE

02/12/2026